

# Mandibular Defect Reconstruction Using Three-Dimensional Polycaprolactone Scaffold in Combination with Platelet-Rich Plasma and Recombinant Human Bone Morphogenetic Protein-2: *De Novo* Synthesis of Bone in a Single Case

Karl-Heinz Schuckert, D.M.D., M.D., Ph.D.,<sup>1</sup> Stefan Jopp, M.D., Ph.D.,<sup>1</sup> and Swee-Hin Teoh, Ph.D.<sup>2</sup>

This publication describes the clinical case of a 71-year-old female patient. Using polycaprolactone (PCL) scaffold, platelet-rich plasma (PRP) and recombinant human bone morphogenetic protein-2 (rhBMP-2), a critical-sized defect in the anterior mandible was regenerated using *de novo*-grown bone. A bacterial infection had caused a periimplantitis in two dental implants leading to a large destruction in the anterior mandible. Both implants were removed under antibiotic prophylaxis. A PCL scaffold was prepared especially for this clinical case. In a second procedure with antibiotic prophylaxis, the bony defect was reopened. The PCL scaffold was fitted and charged with PRP and rhBMP-2 (1.2 mg). After complication-free wound healing, the radiological control demonstrated *de novo*-grown bone in the anterior mandible 6 months postoperatively. Dental implants were inserted in a third operation. A bone biopsy of the newly grown bone, as well as of the bordering local bone, was taken and histologically examined. The bone samples were identical and presented vital laminar bone.

## Introduction and Scientific Background

**T**RADITIONALLY, THE AUGMENTATION of bony defects is carried out using allografts, xenografts, autogenous bone, and synthetic biomaterials. The transplantation of autogenous bone is regarded as the gold standard. Globally, there are more than 2 million autogenous bone transplantations in humans each year.<sup>1,2</sup>

Because of the osteoinductive and osteoconductive character<sup>3</sup> of autogenous bone, there are a number of good results obtained upon transplantation. However, there are disadvantages, namely:

1. In most cases, two surgical procedures are necessary: one for bone harvesting (e.g., from the iliac crest) and the other for implantation. This can cause some patients to suffer from complications associated with the donor site.
2. At the site of bone transplantation, the risks of wound infection, necrosis, and resorption, representing up to 30% of transplanted material, have been experienced.<sup>1,2</sup>

The use of growth factors such as recombinant human bone morphogenetic protein (rhBMP) and differentiated stem cells has broken new ground in bone tissue engineering.

Since the first publication by Urist in 1965 regarding bone growth by induction,<sup>4</sup> there have been several thousand international publications on this strategy. For oral and maxillofacial surgery, Nevins *et al.*,<sup>5</sup> Boyne *et al.*,<sup>6</sup> Terheyden *et al.*,<sup>7</sup> Barboza *et al.*,<sup>8</sup> and Ripamonti *et al.*<sup>9</sup> have reported newly regenerated bone in animal models using growth factors. Nevins worked with goats, Boyne with *Macaca fascicularis* (rhesus) monkeys, Terheyden with miniature pigs, Barboza with dogs, and Ripamonti with chacma baboons. All these animal studies were carried out in the field of oral and maxillofacial surgery. Except Terheyden, who used rhBMP-7 (osteogenetic protein 1 (OP)-1, Stryker, Kalamazoo, MI), all other authors used rhBMP-2 (INFUSE, U.S.; InductOs, Europe; Wyeth, Madison, NJ). Boyne *et al.*,<sup>10</sup> Cochran *et al.*,<sup>11</sup> Wikesjö *et al.*,<sup>12</sup> Fiorellini *et al.*,<sup>13</sup> and Boyne *et al.*<sup>14</sup> published the first clinical studies of bone regeneration in humans with rhBMP-2 in dental applications. Jung *et al.*<sup>15</sup> (rhBMP-2) and Warnke *et al.*<sup>16</sup> (rhBMP-7) combined xenogenic deproteinized natural bone mineral (NBM) with BMPs for jawbone reconstruction in single cases. The other common material used is bovine collagen. OP-1 contains a mixture of rhBMP-7 powder and granulated absorbable collagen sponge (ACS). INFUSE/InductOs is provided as rhBMP-2 powder and a separate collagen sponge (ACS). Only

<sup>1</sup>Institute Indente – Institute of Innovative Oral Surgery and Medicine, Centre for Tissue Engineering, Hannover, Germany.

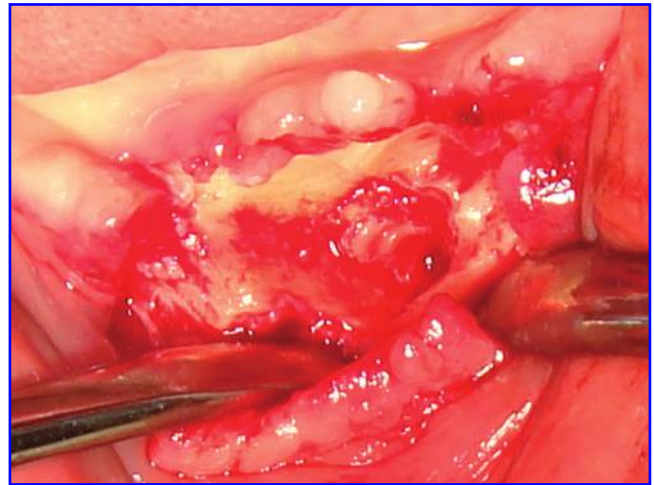
<sup>2</sup>Center for Biomaterials Applications and Technology, Department of Mechanical Engineering, National University of Singapore, Singapore.

INFUSE/InductOs enables a complete splitting of both parts. ACS was not used because it is a xenogenic material that leads to immunological reactions in 18% of patients.<sup>17</sup> Moreover, ACS is not able to provide suitable structural support for the agglomeration of osteoblasts to reconstruct larger bony defects.<sup>18</sup>

We have demonstrated the advantages of using rhBMP-2 in combination with other carrier materials and scaffolds instead of ACS.<sup>18</sup> Whereas Boyne<sup>10,14</sup> used 1.7 to 3.4 mg<sup>10</sup> or 12 to 24 mg (1.5 mg/mL)<sup>14</sup> rhBMP-2 in combination with ACS per sinus floor augmentation, we achieved comparable results by combining rhBMP-2 with demineralized bone matrix using 1.3 to 1.5 mg (1.5 mg/mL) rhBMP-2. The augmentation material should possess the following features.

1. Preferably, the material used as a scaffold ought to be of synthetic origin and completely biodegradable or resorbable, with interconnected pores large enough for nutrient and waste product transport and micro-architecture that facilitates the adhesion of cells and proteins. It also needs to be load-bearing (with low stability of the surrounding bone) and durable to avoid premature failure during the tissue remodeling phase.
2. In addition, endogenous components such as platelet-rich plasma (PRP) and stem cells need to be incorporated to perform the function beyond tissue regeneration to tissue remodelling. This includes constant receipt of cellular components and the possibility of nutrition through vascularization of these cellular components, aiming at a constant effect on bone regeneration.

Hutmacher<sup>19</sup> and Zein<sup>20</sup> have presented a suitable three-dimensional (3D) polycaprolactone (PCL) scaffold that can be used for augmentation purposes. These scaffolds have been tested as delivery systems for PRP<sup>21</sup> and for rhBMP-2.<sup>22,23</sup> Wiltfang *et al.*,<sup>24</sup> Choi *et al.*,<sup>25</sup> Fennis *et al.*,<sup>26</sup> Okuda *et al.*,<sup>27</sup> Marx *et al.*<sup>8</sup> and Freymiller *et al.*<sup>29</sup> have previously reported the positive effect of PRP on bone regeneration. Wiltfang demonstrated a significant effect on bone regeneration in mini-pigs using a combination of PRP, tricalcium phosphate (TCP), and autogenous bone. Choi demonstrated the advantage of PRP on bone regeneration in combination with autogenous bone grafts over autogenous bone alone in a canine model. Fennis compared autogenous irradiated cortical scaffolds with PRP and autogenous bone graft from the iliac crest of goats versus the original bone alone in bridging the defect. All goats had undergone bone remodeling. Okuda presented a comparative controlled clinical study in humans using PRP combined with porous hydroxyapatite grafts for the treatment of intrabony periodontal defects. He compared these results with a control group without PRP. His results showed significantly better clinical improvement in the test group than in the control group. Marx pointed out the relevance of platelet-derived growth factors (PDGF<sub>aa</sub>, PDGF<sub>3/3</sub>, PDGF<sub>ab</sub>) and transforming growth factors (TGF- $\alpha$  and TGF $\beta$ 2) for bone regeneration. Freymiller presented an overview of different scientific papers. Because of the different conditions of these studies, he pointed out that the results could not be compared. Basically, the use of PRP in bone regeneration has improved the results in bone surgery. Comparing studies will be necessary in the future to strengthen the results of the




**FIG. 1.** Intraoperative situation after removal of dental implants. Color images available online at [www.liebertonline.com/ten](http://www.liebertonline.com/ten).

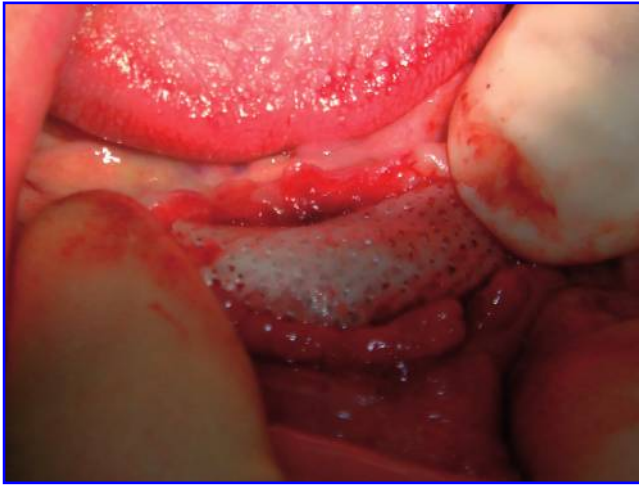reporting authors. In a clinical study in dogs, Rai *et al.*<sup>30</sup> have regenerated critical-sized defects of the mandible with PCL and 20% TCP scaffolds in combination with PRP. The bone regenerated with PCL + TCP scaffolds and PRP was of a higher quality and density than the bone regenerated without PRP. Teoh<sup>31</sup> and his clinical team demonstrated the first application of the 3D fused deposition modelled PCL scaffold combined with medical imaging and with osteoblast cells, leading to a reasonably successful regeneration of a large craniofacial bony defect in a human being. In this article, we report the first successful clinical case of the reconstruction of the anterior mandible on an osteoporotic patient using the 3D PCL scaffold in combination with PRP and rhBMP.

## Materials and Methods

Periimplantitis caused by bacterial infection often leads to bone loss around dental implants. Subject to favorable conditions, with the use of antibiotics, photodynamic therapy,



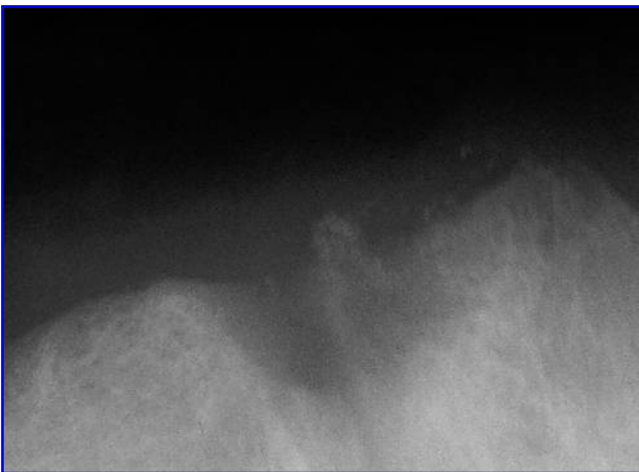
**FIG. 2.** Three-dimensional polycaprolactone scaffold. Color images available online at [www.liebertonline.com/ten](http://www.liebertonline.com/ten).



**FIG. 3.** Three-dimensional polycaprolactone scaffold *in situ*. Color images available online at [www.liebertonline.com/ten](http://www.liebertonline.com/ten).

and modern bone regeneration, healing is possible, leaving the implants *in situ*.<sup>32</sup> Advanced infections and large bony defects require implant removal under antibiotic prophylaxis before reconstructing the defects. The case of a 71-year-old female patient showed two dental implants in the anterior mandible. The region had a profound periimplantitis with considerable bony defect. After a bacterial infection, treatment with an antibiotic (amoxicillin 3×1000 mg/day over 2 weeks) was administered, and the titanium implants were removed (Fig. 1). Using PRP, the bony defect was closed. This procedure was performed under local anesthesia, analgesation, and close monitoring. After this first intervention, the wound healing was complication-free.

A PCL scaffold was custom manufactured for this defect after optical and radiological measurements (Fig. 2). Osteopore International Pte Ltd. Singapore produced and designed the PCL scaffold, which had a porosity of 75%, under current good manufacturing practices in a clean room in compliance with International Standards Organization 13485.



**FIG. 4.** Preoperative X-ray, bony defect of anterior mandible.

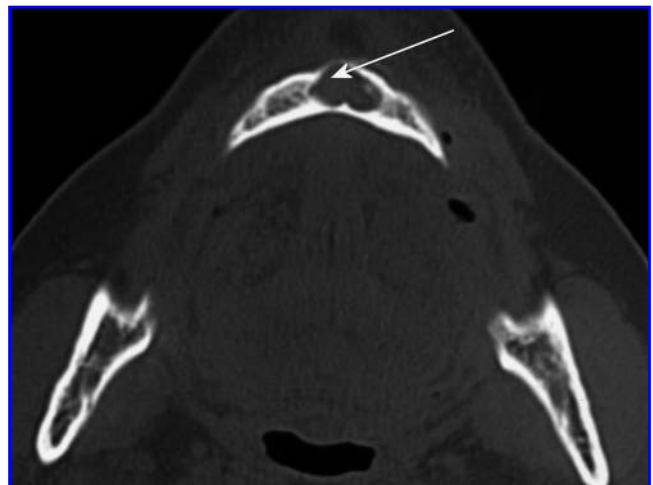


**FIG. 5.** Four-month postoperative X-ray, mostly total reconstruction of bony defect through *de novo* grown bone.

The scaffold was fabricated in a pyramidal shape in the center of a broad-base mesh. The latter was designed for ease of tissue anchoring and minimizes any micromotion. Under antibiotic treatment, the scaffold, loaded with PRP and rhBMP-2 (InductOs, Wyeth, 1.2 mg), was implanted in a second operation (Fig. 3). The pyramidal scaffold was inserted upside down into the bony defect and fixed by the base mesh, which was designed to hold the scaffold in position and prevent any micromotion. The 3D PCL scaffold was ideally suited for the defect. This procedure was also performed under local anesthesia and analgesation and monitored accordingly.

## Results

One week after implantation of the 3D-PCL scaffold with PRP and rhBMP-2, complication-free wound healing permitted removal of the sutures, and the patient was able to wear her dentures again. Controls were made at intervals of



**FIG. 6.** Preoperative computed tomography: large bony defect in anterior mandible.

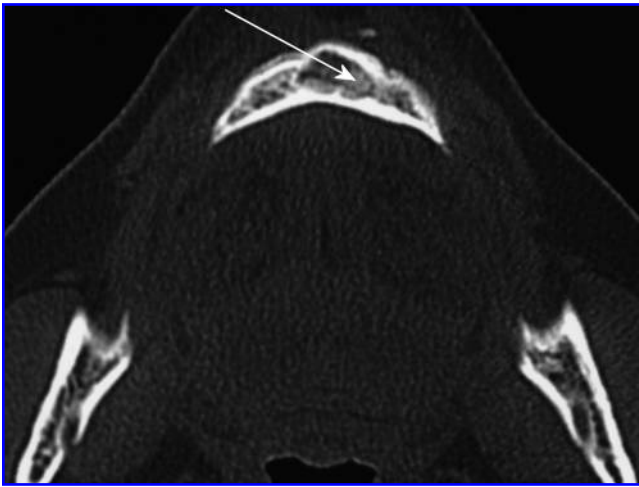


FIG. 7. Six-month postoperative computed tomography: former bony defect reconstructed with *de novo* grown bone.

2 to 3 weeks. Compared with the preoperative situation (Fig. 4), the first X-ray, taken 4 months after augmentation (Fig. 5) (Siemens Heliodont, 70 KV, 7 mA, 0.16s), already showed clear growth of bone in the operating field. In contrast to the preoperatively taken computed tomography (CT; X vision 130 KV/400 mAs) (Fig. 6) showing a large bony defect in the anterior mandible, the 6-month postoperative control CT (Fig. 7) shows a dense bone structure in the area of the former defect. In Table 1, a grey-value histogram displays the increase in bone density. Average grey values of the local bone have been compared with average values of the augmentation area preoperatively (Fig. 6) and 6 months postoperatively (Fig. 7). The obvious increase shows the *de novo*-grown bone.

In a third surgical procedure, two new dental implants were placed into the newly grown bone to enable a tight-fitting mandibular denture; a radiological control was made (Fig. 8) (Siemens Orthopantomograph, 70 KV, 15 mA). Two bone biopsies of the augmented area were taken using a trephine drill ( $\varnothing$  2.5 mm) before setting the implants in the same place. Histological analyses were made on a part of each specimen (Fig. 9, 10). The other parts were used for micro-CT analysis (Fig. 11). From the bordering local bone, a small bone ridge had to be removed to avoid injury of soft tissue by the integrated denture that was later implanted. The bone biopsies were taken for histological analysis (Fig. 12). All histological analyses, of the local bone as well as of the newly grown bone, showed vital laminar bone. As with Wellmann,<sup>33</sup> we preferred micro-CT for analysis of bone

TABLE 1. GREY-VALUE HISTOGRAM SHOWING THE QUOTIENT OF AVERAGE GREY VALUE IN THE OPERATION FIELD PRE- (FIG. 6) AND POSTOPERATIVE (FIG. 7) COMPARED WITH THE AVERAGE GREY VALUE OF LOCAL BONE

	Average grey value - local bone	Average grey value - operating field		Quotient
Fig. 6	139	bony defect	77	0.55
Fig. 7	147	new grown bone	121	0.82

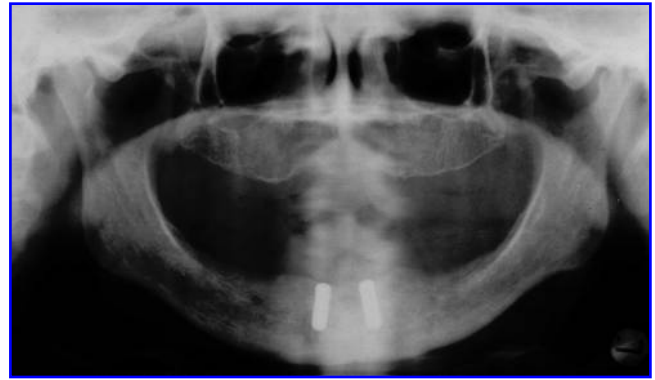


FIG. 8. Orthopantomographic: two dental implants *in situ*.

density classification instead of procedures like dual-energy X-ray absorptiometry, quantitative CT, or ultrasound. In contrast to all other methods, micro-CT also displays the micro-architecture of the new grown bone.

The bone densities of the micro-CTs of the augmentation area are presented in Table 2. The micro-CT was performed using the SkyScan 1076.

Three months after having set the implants, the gingiva above was removed, and a bar construction to stabilize a denture was prepared and screwed in (Fig. 13).

## Discussion

Since the first publication by Urist in 1965<sup>4</sup> on bone induction via growth factors, a number of animal models and clinical studies on bone regeneration with BMPs have been performed. From 2002 onward, rhBMP-2 and rhBMP-7 have been available as therapeutics for use in humans. In both cases, bovine collagen (ACS) served as the carrier material, but bovine collagen is a xenogenic material that may cause adverse immune reactions and has poor mechanical stability. Thus, ACS was not used in this case.<sup>17</sup>

Combining PCL, PRP, and rhBMP-2, a controlled release of growth factors is possible.<sup>21-23</sup> To the authors' best

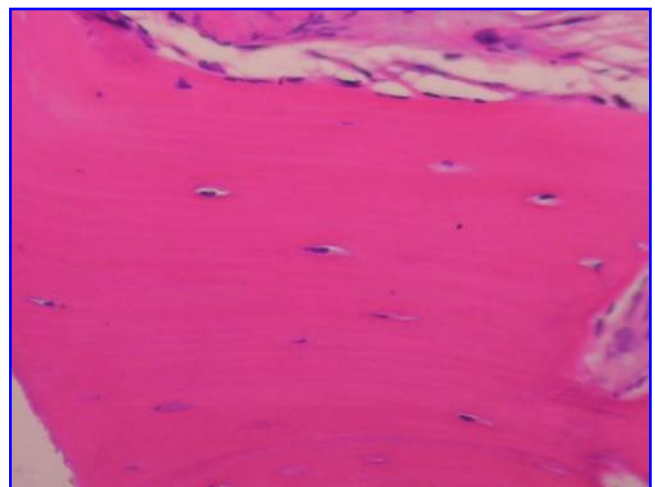


FIG. 9. Histology of *de novo*-grown bone (right specimen). Color images available online at [www.liebertonline.com/ten](http://www.liebertonline.com/ten).

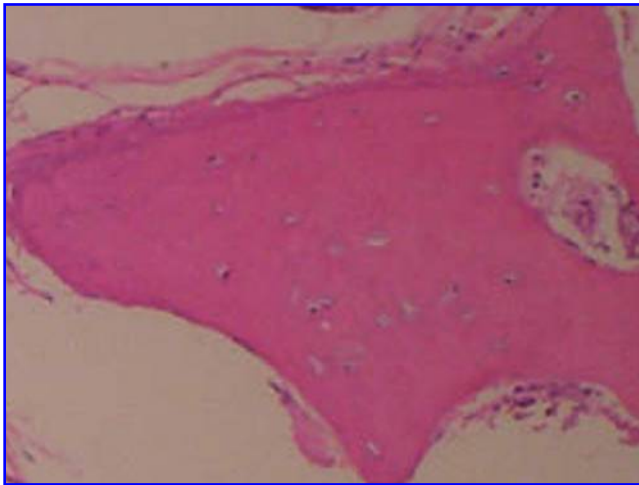


FIG. 10. Histology of *de novo*-grown bone (left specimen). Color images available online at [www.liebertonline.com/ten](http://www.liebertonline.com/ten).

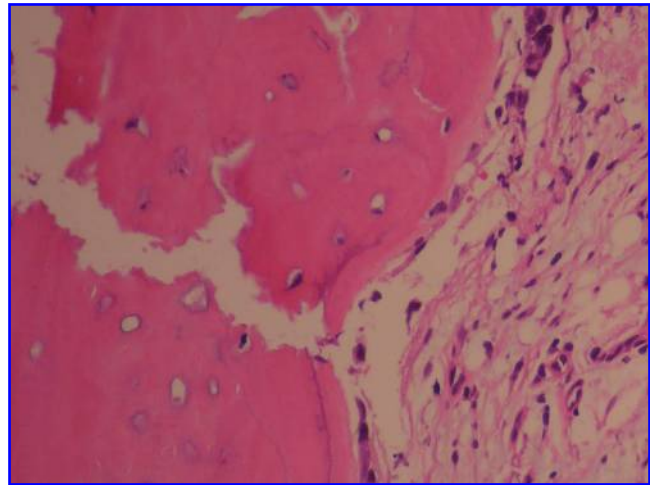


FIG. 12. Histology of bordering local bone. Color images available online at [www.liebertonline.com/ten](http://www.liebertonline.com/ten).

knowledge, this single case is the first that has been done successfully to regenerate new bone in a critical defect of the mandible adopting the strategy of a load-bearing 3D PCL scaffold with PRP and rhBMP-2. The harvesting of autogenous bone and its transplantation, so far the only safe alternative, was thereby avoided. Based on these results and the effects of combination of the 3D PCL with mesenchymal stem cells,<sup>31</sup> it is clearly indicative of a real alternative to autogenous bone transplantation, especially for patients with absolute or relative contraindication for bone removal. This must be considered particularly with regard to the well-known problems at the donor region and for the recipient organism as well. Springer *et al.* and Macacci *et al.* have

published similar positive results as to the combination of scaffolds and periosteal<sup>3</sup> and stem cells,<sup>34</sup> respectively.

Considering bone density in Table 1, the different development of both samples requires an explanation. Because the total degradation time of PCL takes longer than 6 months, the rest of the undegraded PCL could have remained upon bone biopsy. Shorter biodegradability of the scaffold would be desirable. It should be optimally adapted to the new bone development and be completed after 3 to 4 months. Springer *et al.* reports on xenogene NBM retarding complete absorption. In places, the material had not decomposed at all. The use of porous hydroxyapatite ceramic scaffolds by Marcacci *et al.* radiologically shows part of the scaffold after several years. For scaffolds to be used in the future, it must be required that they biodegrade upon bone regeneration and will not persist on *de novo*-grown bone any longer than necessary.

It must be considered that there are different results in human and animal bone regeneration, depending on the time of bone regeneration and the time of biodegradation or resorption of different materials. Under clinical view, the periods are longer in humans than in animal models (e.g., canines, dogs, goats). There are also important intra- and inter-individual differences in patients due to their individual clinical situation. Further studies are required for clarification.

Significant comparative studies on the use of rhBMP-2 versus rhBMP-7 with the same indication are missing. Studies on bone regeneration comparing the use of mesenchymal stem cells with BMPs are missing as well.

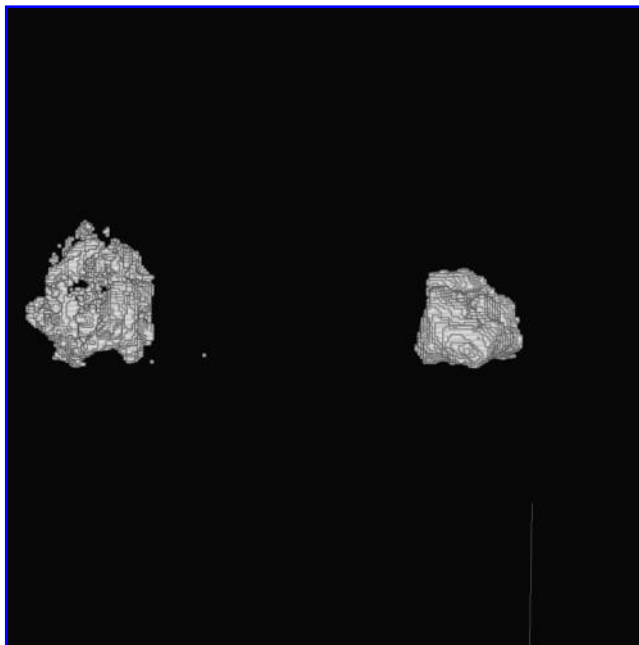
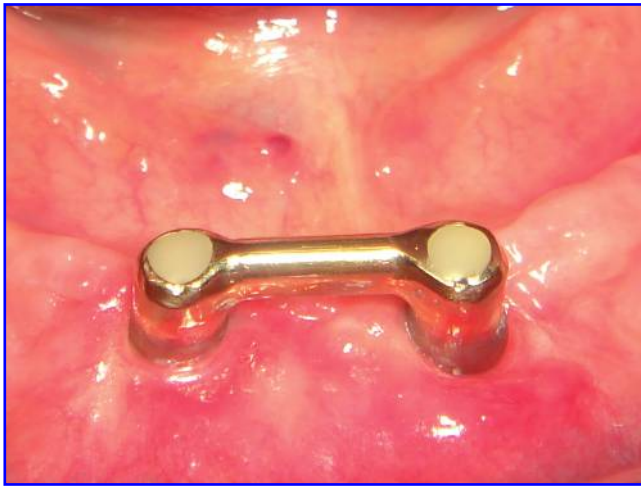


FIG. 11. Micro-computed tomography of *de novo*-grown bone.

TABLE 2. MICRO COMPUTED TOMOGRAPHY ANALYSIS SHOWING THE BONE VOLUME IN PERCENTAGE OF THE TOTAL VOLUME

Sample	Volume	Bone Volume/Sample Volume
1	10.85 mm <sup>3</sup>	4.9 %
2	5.29 mm <sup>3</sup>	2.4 %

The bone samples were taken from the augmentation area.



**FIG. 13.** Bar construction. Color images available online at [www.liebertonline.com/ten](http://www.liebertonline.com/ten).

Schmelzeisen *et al.*<sup>35</sup> and Warnke *et al.* have invented other techniques.<sup>16</sup> Schmelzeisen has developed a method of growing human bone *in vitro* for subsequent implantation in humans. Warnke has grown bone ectopically in musculature for transplantation into the mandible. These techniques require newly grown bone to be transplanted to the recipient site. Due to this fact, problems similar to the transplantation of autogenous bone may occur because of infection, necrosis, and resorption. As demonstrated in this single case and as presented analogically by Springer *et al.*<sup>3</sup> and Marcacci *et al.*,<sup>34</sup> bone regeneration *in vivo* avoids completely transplantation and the accompanying risks, although this technique requires implantation in an abacterial region. Moreover, the constitution of the soft tissue as epithelium must be able to allow primary wound healing. Bone regeneration *in vivo* will have the best results when no wound infection occurs.

Regarding different scaffolds in combination with growth factors and/or stem cells, further research will be necessary to define the results of bone healing. Further clinical studies are necessary to develop bone regeneration *in vivo* with different scaffolds in combination with growth factors and/or stem cells.

### Acknowledgments

This single clinical case was performed with the knowledge of the ethical authorities. Unlike clinical studies, in the run-up to those single cases, no written application or final acceptance is required.

The authors wish to thank Miss Bina Rai, Mr. Jochen Eichholtz, Dr. Münch, and Prof. Maschek for their technical support.

### References

1. Betz, R.R. Limitations of autograft and allograft: new synthetic solutions. *Orthopedics* **25**, 561, 2002.
2. Horch, H-H., Pautke, C. Regeneration instead of reparation. *Mund Kiefer Gesichtschir* **10**, 213, 2006.
3. Springer, I.N., Nocini, P.F., Schlegel, K.A., de Santis, D., Park, J., Warnke, P.H., Terheyden, H., Zimmermann, R., Chiarini, L., Gardner, K., Ferrari, F., Wiltfang, J. Two techniques for the preparation of cell-scaffold constructs suitable for sinus augmentation: steps into clinical application. *Tissue Eng* **12**, 2649, 2006.
4. Urist, M.R. Bone: formation by autoinduction. *Science* **150**, 893, 1965.
5. Nevins, M., Kirker-Head, C., Nevins, M., Wozney, J.A., Palmer, R., Graham, D. Bone formation in the goat maxillary sinus induced by absorbable collagen sponge implants impregnated with rhBMP-2. *Int J Periodontics Restorative Dent* **16**, 8, 1996.
6. Boyne, P.J. Animal studies of application of rhBMP-2 in maxillofacial reconstruction. *Bone* **19**, 83, 1996.
7. Terheyden, H., Jepsen, S., Moeller, B., Tucker, M.M., Rueger, D.C. Sinus floor augmentation with simultaneous placement of dental implants using a combination of deproteinized bone xenografts and recombinant human osteogenic protein-I. *Clin Oral Implants Res* **10**, 510, 1999.
8. Barboza, E.P., Duarte, M.E., Geolas, L., Geolás, L., Sorensen, R.G., Wikesjö, U.M. Ridge augmentation following implantation of rhBMP-2 in the dog. *J Periodontol* **71**, 488, 2000.
9. Ripamonti, U., Crooks, J., Petit, J.C., Rueger, D.C. Periodontal tissue regeneration by combined applications of recombinant human osteogenic protein-1 and bone morphogenetic protein-2. A pilot study in Chacma baboons (*Papio ursinus*). *Eur J Oral Sci* **109**, 241, 2001.
10. Boyne, P.J., Marx, R.E., Nevins, M., Triplett, G., Lazaro, E., Lilly, L.C., Alder, M., Nummikoski, P. A feasibility study evaluating rhBMP-2/absorbable collagen sponge for maxillary sinus floor augmentation. *Int J Periodontics Restorative Dent* **17**, 11, 1997.
11. Cochran, D.L., Jones, A.A., Lilly, L.C., Fiorellini J.P., Howell, H. Evaluation of recombinant human bone morphogenetic protein-2 in oral applications including the use of endosseous implants: 3-year results of a pilot study in humans. *J Periodontol* **71**, 1241, 2000.
12. Wikesjö, U.M., Qahash, M., Thomson, R.C., Cook, A.D., Rohrer, M.D., Wozney, J.M., Hardwick, W.R. rhBMP-2 significantly enhances guided bone regeneration. *Clin Oral Implants Res* **15**, 194, 2004.
13. Fiorellini, J., Howell, T., Cochran, D., Malmquist, J., Lilly, L.C., Spagnoli, D., Toljanic, J., Jones, A., Nevins, M. Randomized study evaluating rhBMP-2 for extraction socket augmentation. *J Periodontol* **76**, 605, 2005.
14. Boyne, P.J., Lilly, L.C., Marx, R.E., Moy, P.K., Nevins, M., Spagnoli, D. *De novo* bone induction by recombinant human bone morphogenetic protein-2 (rhBMP-2) in maxillary sinus floor augmentation. *J Oral Maxillofac Surg* **63**, 1693, 2005.
15. Jung, R.E., Glauser, R., Scharer, P., Hammerle, C.H., Sailer, H.F., Weber, F.E. Effect of rhBMP-2 on guided bone regeneration in humans. *Clin Oral Implants Res* **14**, 556, 2003.
16. Warnke, P.H., Springer, I.N., Wiltfang, J., Acil, Y., Eufinger, H., Wehmöller, M., Russo, P.A., Bolte, H., Scherry, E., Behrens, E., Terheyden, H. Growth and transplantation of a custom vascularised bone graft in a man. *Lancet* **364**, 766, 2004.
17. Medtronic Sofamor Danek, Inc. USA. Summary of Safety and Effectiveness Data, INFUSE™ Bone Graft, July 2, 2002.
18. Schuckert, K.H., Jopp, S., Müller, U. Bone tissue engineering with BMPs—first experiences and results in oral surgery by using rhBMP-2 in humans. *Int J Oral Maxillofac Surg* **34**, 68, 2005.

19. Hutmacher, D.W. Scaffolds in tissue engineering bone and cartilage. *Biomaterials* **21**, 2529, 2000.
20. Zein, I., Hutmacher, D.C., Tan, K.C., Teoh, S.H. Fused deposition modeling of novel scaffold architectures for Tissue Engineering applications. *Biomaterials* **23**, 1169, 2002.
21. Rai, B., Teoh, S.H., Ho, K.H. An evaluation of PCL-TCP composites as delivery systems for platelet rich plasma. *J Control Release* **107**, 330, 2005.
22. Rai, B., Teoh, S.H., Ho, K.H., Hutmacher, D.W., Cao, T., Chen, F., Yacob, K. The effect of rhBMP-2 on canine osteoblasts seeded onto 3D bioactive polycaprolactone scaffolds. *Biomaterials* **25**, 5499, 2004.
23. Rai, B., Teoh, S.H., Hutmacher, D.W., Cao, T., Ho, K.H. Novel PCL-based honeycomb scaffolds as drug delivery systems for rhBMP-2. *Biomaterials* **26**, 3739, 2005.
24. Wiltfang, J., Kloss, F.R., Kessler, P., Nkenke, E., Schultze-Mosgau, S., Zimmermann, R., Schlegel, K.A. Effects of platelet-rich plasma on bone healing in combination with autogenous bone and bone substitutes in critical size defects. *Clin Oral Implants Res* **15**, 187, 2004.
25. Choi, B.H., Im, C.J., Huh, J.Y., Suh, J.J., Lee, S.H. Effect of platelet rich plasma on bone regeneration in autogenous bone graft. *Int J Oral Maxillofac Surg* **33**, 56, 2004.
26. Fennis, J.P.M., Stoelinga, P.J.W., Jansen, J.A. Reconstruction of the mandible with an autogenous irradiated cortical scaffold, autogenous corticocancellous bone-graft and autogenous platelet-rich plasma: an animal experiment. *Int J Oral Maxillofac Surg* **34**, 158, 2005.
27. Okuda, K., Tai, H., Tanabe, K., Suzuki, H., Sato, H., Kawase, T., Saito, Y., Wolff, L.F., Yoshiex, H. Platelet-rich plasma combined with a porous hydroxyapatite graft for the treatment of intrabony periodontal defects in humans: a comparative controlled clinical study. *J Periodontol* **76**, 890, 2005.
28. Marx, R.E. Platelet rich plasma: evidence to support its use. *J Oral Maxillofac Surg* **62**, 489, 2004.
29. Freymiller, E.G., Aghaloo, T.L. Platelet-rich plasma: ready or not. *J Oral Maxillofac Surg* **62**, 484, 2004.
30. Rai, B., Ho, K.H., Lei, Y., Si-Hoe, K.M., Jeremy Teo, C.M., Yacob, K.B., Chen, F., Ng, F.C., Teoh, S.H. Polycaprolactone-20% tricalcium phosphate scaffolds in combination with platelet-rich plasma for the treatment of critical-sized defects of the mandible: a pilot study. *J Oral Maxillofac Surg* **65**, 2195, 2007.
31. Teoh, S.H. Integrating medical imaging and advance manufacturing in development of patient specific load bearing scaffolds for bone tissue engineering. Strategies for Organ Repair, July 1–2, 2003, Erlangen, Germany (Plenary Lecture).
32. Schuckert, K.H., Jopp, S., Müller, U. *De novo* grown bone on exposed implant surfaces using photodynamic therapy and recombinant human bone morphogenetic protein-2: case report. *Implant Dent* **15**, 361, 2006.
33. Wellmann, M., Witte, F., Floerkemeyer, T., Nellesen, J., Crostack, H., Raschke, M., Windhagen, H. Non-invasive prediction of multiaxial stiffness of callus tissue: comparison of bone mineral density (BDM) vs trabecular 3D micro-architecture. German Medical Science Doc E.4.2-1379, 2006.
34. Marcacci, M., Kon, E., Moukhachev, V., Lavroukov, A., Kutepov, S., Quarto, R., Mastrogiacomo, M., Cancedda, R. Stem cells associated with macroporous bioceramics for long bone repair: 6- to 7-year outcome of a pilot clinical study. *Tissue Eng* **13**, 947, 2007.
35. Schmelzeisen, R., Schimmig, R., Sittinger, M. Making bone: implant insertion into tissue-engineered bone for maxillary sinus floor augmentation—a preliminary report. *J Cranio-maxillofac Surg.* **31**, 34, 2003.

Address reprint requests to:  
 Karl-Heinz Schuckert, D.M.D., M.D., Ph.D.  
 Institute Indente  
 Ellernstraße 23  
 30175 Hannover  
 Germany

E-mail: info@indente.de

Received: January 17, 2008

Accepted: May 21, 2008

Online Publication Date: August 29, 2008

